

Diagnosis and Management of Plateau Iris

Plateau iris is an ocular anatomic variant that may increase the risk of primary angle-closure glaucoma (PACG) and potential vision loss. It is typically diagnosed in patients 30 to 50 years old who have a persistently narrow angle following a patent laser peripheral iridotomy (LPI). Plateau iris configuration is usually characterized by either an anterior iris insertion on the ciliary body or an anterior rotation of the ciliary body itself, leading to narrowing of the iridotrabeular angle. Pupillary block is often present concurrently. Understanding and identifying key features of plateau iris is fundamental in decreasing the risk of glaucomatous vision loss in susceptible eyes, especially in patients under 50 years old.

Epidemiology

The exact incidence of plateau iris is not well known. Patients tend to be female with an average age of 40 years at presentation. One study found plateau iris, as identified on ultrasound biomicroscopy (UBM), in 32% of primary angle closure suspect eyes (PACS) after LPI in individuals over 50 years old.¹ Another study found plateau iris in 54% of those patients under 60 where angle closure symptoms persisted in spite of a patent LPI.² In many cases, family history is positive for angle-closure glaucoma.³ Eyes with plateau iris can be hyperopic, but to a lesser degree than those with angle closure from pupillary block. Further, it is important

to suspect plateau iris in young myopes with narrow or closed angles.

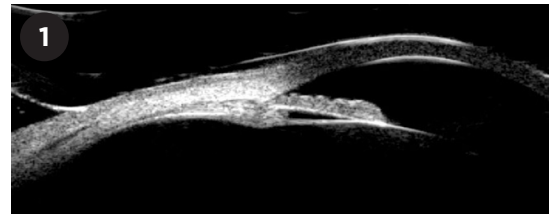
Pathophysiology

Plateau iris is typically caused by anterior rotation of the ciliary body but can also result from an anomalous anterior iris root insertion onto the ciliary body itself. In either form, the peripheral iris is pushed forward, leading to appositional closure of the angle. Notably, patients with plateau iris often have some degree of pupillary block.

Plateau iris can be categorized into two subtypes differentiated by the presence or absence of a patent LPI. The term plateau iris configuration (PIC) describes an eye with a narrow angle on gonioscopy, no LPI, and a deep central anterior chamber. Plateau iris syndrome (PIS) describes an eye with a deep central anterior chamber and persistently narrow or closed angle on gonioscopy despite a patent LPI that has presumably eliminated any element of pupillary block. In both subtypes, the anomalous iris position leads to angle obstruction and compromised trabecular meshwork (TM) outflow facility.

Features and Presentation

Patients with plateau iris are typically female, between 30 and 50 years old, and hyperopic. Frequently, they are



UBM. Narrow angle and anteriorly rotated ciliary body in a patient with plateau iris.

identified on routine ophthalmic examination without reported symptoms. Thus, it is imperative for the clinician to consider plateau iris in any patient being evaluated for narrow angles, even in eyes with prior LPI. Myopic refractive error does not exclude anomalous angle anatomy, so clinical suspicion should be maintained in myopic eyes with narrow angles.

Symptomatic patients have a presentation similar to those undergoing a classic angle-closure attack, with elevated IOP, nausea, vomiting, headache, eye pain, and photophobia.

Examination findings. On exam, the central anterior chamber depth is normal, although the peripheral chamber can appear shallow. The iris plane is typically flat.

Gonioscopy is an important diagnostic tool in identifying plateau iris. The angle is usually narrow or closed, and the iris is flat. Indentation gonioscopy reveals the “double-hump sign”: the peripheral hump corresponds to tissue draping over the ciliary body, and the proximal hump is created by the iris draping over the lens.

On gonioscopy, two types of PIS can be discerned. Complete PIS de-

scribes an angle occluded to the upper portion of the TM, leading to increased IOP. Incomplete PIS describes an angle occluded to the lower portion of the TM. The anterior portion remains functional and able to maintain sufficient outflow facility. However, peripheral anterior synechiae can form over time, subsequently leading to progressive IOP elevation.

Diagnosis

The differential diagnosis for plateau iris includes PACG secondary to pupillary block, phacomorphic angle closure, iris cysts causing secondary narrowing of the angle, and an incomplete LPI.

Apart from gonioscopy, UBM can facilitate identification of plateau iris by revealing the pertinent anterior segment configuration and ciliary body abnormalities in detail (Fig. 1). Affected eyes display an anteriorly rotated ciliary body and may also have a shortened iris root with anomalous anterior insertion onto the ciliary body. Anterior segment OCT can confirm pupillary block but is less useful for imaging ciliary body pathology. Also, it is not a dynamic examination technique and provides less information than gonioscopy or UBM.

Management

Medical. Although the treatment of plateau iris is typically surgical, some physicians begin with medical management. Low-dose pilocarpine induces contracture of the iris sphincter and ciliary body, pulling the iris away from the TM and widening the angle. However, clinicians should discuss common complaints such as brow ache, vision changes secondary to miosis, or other adverse effects with their patients.

Laser therapy. LPI is usually the first intervention that is performed in eyes with narrow angles or PIC, as eyes with plateau iris frequently also have an element of pupillary block. If the patient continues to have persistent apposition of the iridocorneal angle or develops elevated IOP, an argon laser peripheral iridoplasty (ALPI) can be performed. Low power, long duration, and large-sized burns are placed at the peripheral iris, inducing contracture of the iris stroma and retraction away

from the angle.

ALPI has been associated with complications: IOP spikes, transient iritis, iris atrophy, and Urrets-Zavalía syndrome have all been reported.⁴ Moreover, it is not clear whether ALPI provides adequate long-term control of IOP and appositional angle closure.

Incisional surgery. If medical and laser options fail to control IOP, incisional surgery should be considered. Traditionally, these options included trabeculectomy or glaucoma drainage devices with or without goniosynechialysis. However, results of recent studies have shown other surgical treatments such as lens-based surgery to be safe and efficacious. For example, the EAGLE trial found clear lens extraction to be a more successful and cost-effective solution for PACG than LPI and recommended that it be considered for first-line treatment.⁵ Another option is cataract surgery with endocyclophotocoagulation (ECP), which can simultaneously lower IOP and open the angle through the combined mechanisms of lens removal and contracture of the ciliary processes.⁶

The continuous expansion of minimally invasive glaucoma surgery techniques has further extended the range of potential treatment, with some surgeons electing to add procedures like goniotomy with the Kahook Dual Blade (New World Medical) to augment the effect of cataract extraction.⁷

Because plateau iris tends to occur in patients who may not have visually significant cataracts, the risks and benefits of surgical intervention should be assessed on an individualized basis.

Complications. The unusual anatomy of eyes with plateau iris can lead to unique complications and treatment considerations. These eyes tend to have a smaller sulcus diameter as well as a narrower interplicata diameter compared with healthy eyes.⁸ In such cases, the square-edge haptic of a single-piece IOL in the capsular bag can rub against the ciliary processes and cause in-the-bag uveitis-glaucoma-hyphema (UGH) syndrome.

Two treatment modalities for UGH syndrome have been suggested in the literature. ECP can shrink the ciliary

processes away from the IOL haptics, resolving the uveal chafe. Alternatively, the single-piece lens can be exchanged for a three-piece lens in the bag; the smaller profile of the round polypropylene haptics of a three-piece lens may have less potential to cause mechanical trauma against the ciliary processes compared with the larger square-edged haptics of a single-piece lens.⁹

Conclusion

Plateau iris is an uncommon anatomical variant that predisposes a patient to PACG, and proper diagnosis is essential to preventing glaucomatous vision loss. Plateau iris configuration is characterized by a narrow angle, deep central anterior chamber, and no LPI, whereas plateau iris syndrome describes an eye with a persistently narrow or closed angle despite a patent LPI. Patients with plateau iris syndrome are often younger than those with classic angle-closure glaucoma secondary to pupillary block. Many treatment modalities exist, although the most effective primary treatments are usually surgical. Regular follow-up with serial gonioscopy is critical in monitoring for progression of PIS, as well as the potential development of PACG and vision loss.

1 Kumar RS et al. *Ophthalmology*. 2008;115(3):430-434.

2 Stieger R et al. *Clin Exper Ophthalmol*. 2007;35(5):409-413.

3 Wand M et al. *Trans Sect Ophthalmol Am Acad Ophthalmol Otolaryngol*. 1977;83(1):122-130.

4 Espana EM et al. *Br J Ophthalmol*. 2007;91(4):427-429.

5 Azuara-Blanco A et al. *Lancet*. 2016;388(10052):1389-1397.

6 Francis BA et al. *J Glaucoma*. 2016;25(3):e128-133.

7 Laroche D et al. *J Natl Med Assoc*. 2022;114(1):38-41.

8 Garza PS et al. *Ophthalmol Glaucoma*. 2020;3(6):475-480.

9 Zhang L et al. *J Cataract Refract Surg*. 2014;40(3):490-492.

Dr. Kamat is assistant professor and glaucoma fellowship director in the department of ophthalmology and visual sciences at the University of Texas Southwestern Medical Center, Dallas.
Financial disclosures: None.